

Assessment of vertical changes during maxillary expansion using quad helix or bonded rapid maxillary expander

Cara Conroy-Piskai^a; Maria Therese S. Galang-Boquiren^b; Ales Obrez^c; Maria Grace Costa Viana^d; Nelson Oppermann^e; Flavio Sanchez^e; Bradford Edgren^f; Budi Kusnoto^g

ABSTRACT

Objective: To determine if there is a significantly different effect on vertical changes during phase I palatal expansion treatment using a quad helix and a bonded rapid maxillary expander in growing skeletal Class I and Class II patients.

Materials and Methods: This retrospective study looked at 2 treatment groups, a quad helix group and a bonded rapid maxillary expander group, before treatment (T1) and at the completion of phase I treatment (T2). Each treatment group was compared to an untreated predicted growth model. Lateral cephalograms at T1 and T2 were traced and analyzed for changes in vertical dimension.

Results: No differences were found between the treatment groups at T1, but significant differences at T2 were found for convexity, lower facial height, total facial height, facial axis, and Frankfort Mandibular Plane Angle (FMA) variables. A comparison of treatment groups at T2 to their respective untreated predicted growth models found a significant difference for the lower facial height variable in the quad helix group and for the upper first molar to palatal plane (U6-PP) variable in the bonded expander group.

Conclusion: Overall, both the quad helix expander and the bonded rapid maxillary expander showed minimal vertical changes during palatal expansion treatment. The differences at T2 suggested that the quad helix expander had more control over skeletal vertical measurements. When comparing treatment results to untreated predicted growth values, the quad helix expander appeared to better maintain lower facial height and the bonded rapid maxillary expander appeared to better maintain the maxillary first molar vertical height. (*Angle Orthod.* 2016;86:925–933)

KEY WORDS: Vertical; QuadHelix; Bonded RME; Cephalometric; Transverse

INTRODUCTION

Maxillary expansion is a commonly used treatment modality in orthodontics to correct dental and skeletal

crossbites and to increase the transverse dimension of narrow maxillary arches. The quad helix expander and the bonded rapid maxillary expander are two such expansion appliances that are used for maxillary expansion; however, their mechanisms of action are distinctly different. The basis for rapid maxillary expansion, as achieved with the bonded rapid maxillary expander, is to achieve immediate separation of the midpalatal suture and subsequent deposition of new bone in the suture.¹ The quad helix expander is designed to work more slowly than a rapid maxillary expander, and its construction is less rigid.²

Undesired side effects of palatal expansion that may occur include the extrusion of maxillary molar teeth and an increased vertical dimension.^{1,3–6} Both rapid maxillary expansion with a bonded expander and slow palatal expansion with a quad helix expander have been thought to minimize vertical changes following expansion, which is important for patients who have an increased anterior facial height and/or an increased mandibular plane angle prior to orthodontic treatment.⁷

^a Resident, Department of Orthodontics, School of Dentistry, University of Illinois at Chicago, Chicago, Ill.

^b Assistant Professor, Department of Orthodontics, School of Dentistry, University of Illinois at Chicago, Chicago, Ill.

^c Associate Professor, Department of Restorative Dentistry, School of Dentistry, University of Illinois at Chicago, Chicago, Ill.

^d Statistician, Department of Orthodontics, School of Dentistry, University of Illinois at Chicago, Chicago, Ill.

^e Private Practice, Campinas, Brazil.

^f Private Practice, Greeley, Colo.

^g Associate Professor, Department of Orthodontics, School of Dentistry, University of Illinois at Chicago, Chicago, Ill.

Corresponding author: Dr Budi Kusnoto, Associate Professor, Department of Orthodontics, University of Illinois at Chicago, 801 S. Paulina Street, M/C 841, Chicago, IL 60612

(e-mail: bkusno1@uic.edu)

Accepted: March 2016. Submitted: November 2015.

Published Online: May 16, 2016

© 2016 by The EH Angle Education and Research Foundation, Inc.

The effects of rapid maxillary expansion on the mandible have been shown to result in a downward and backward rotation and a subsequent increase in lower facial height, which has been well documented and studied by several authors.^{1,3-6,8}

The quad helix appliance was first described by Ricketts,⁹ and has gained popularity since as an expansion appliance. The mechanism of action of the quad helix includes rotating the maxillary molars distally, expanding the maxillary molars buccally, and adjusting the anterior arms to expand the maxillary premolar and canine regions.¹⁰ The mechanism of action of the quad helix expander is slow palatal expansion, which is said to be more physiologic than rapid maxillary expansion and may exhibit less relapse.^{11,12}

The bonded rapid maxillary expander is unique because of its incorporation of posterior occlusal coverage into the appliance. This posterior coverage allows for less maxillary molar extrusion because of occlusal forces being directed against the acrylic, and therefore less downward and backward rotation of the mandible.¹³ Treatment with a bonded rapid maxillary expander has also been noted to have an intrusive effect on maxillary first molars,¹⁴ which positively contributes to the maintenance of the vertical dimension.

The objective of this study was to investigate vertical dimension changes between the quad helix expander and the bonded rapid maxillary expander after phase I treatment for growing skeletal Class I and Class II patients. This study also assessed the vertical dimension changes between the quad helix expander and the bonded rapid maxillary expander after phase I treatment for growing skeletal Class I and Class II patients when compared to untreated predicted growth values.

MATERIALS AND METHODS

This was a retrospective study that compared the effects of palatal expansion with a quad helix expander or a bonded rapid maxillary expander in terms of vertical changes in patients with Class I or Class II skeletal patterns. This study was approved by the Institutional Review Board (2013-1147) at the University of Illinois at Chicago.

A total of 35 patients met the inclusion criteria, and based on sample availability with accurate and complete records, 17 patients for the quad helix group and 18 patients for the bonded expander group were used in this study. Of the 17 patients in the quad helix group, five were boys and 12 were girls. Of the 18 patients in the bonded expander group, four were boys and 14 were girls. The mean age before treatment (T1)

and mean treatment time for both the quad helix group and the bonded expander group were calculated, and these data were used for the untreated growth predictions later described. A majority of the patients (80%) in both groups presented with bilateral posterior crossbites, whereas the other 20% has unilateral posterior crossbites. Although the sample size was constrained by the availability of patients undertaking this type of treatment, it was adequate to detect the majority of the existing effects. In addition, a prospective power analysis was not possible because of the absence of known clinically relevant effect sizes across the diverse measurements involved in the study.

All bonded expander patients were obtained consecutively from a single private practitioner with the same protocol, and records were obtained using the same imaging equipment. Similarly, all quad helix expander patients were obtained consecutively from a single private practitioner with the same protocol and imaging equipment.

The patients' lateral cephalometric radiographs were deidentified and classified into two groups: patients treated with a quad helix expander and patients treated with a bonded rapid maxillary expander. The treated patients' lateral cephalograms were uploaded and traced in Dolphin Imaging (Version 11.0.03.37, Chatsworth, Calif) and evaluated at two time points prior to the start of comprehensive orthodontic treatment: T1 and after expansion and stabilization (T2; an average 6-month stabilization period). Specific cephalometric measurements were compared from T1 to T2 within each group and between the two groups to determine if there was a significant difference in vertical changes. Table 1 lists the inclusion and exclusion criteria for the patients in this study. All of the patients were determined to need palatal expansion treatment because of an insufficient maxillary transverse dimension by the orthodontists from whom their records were obtained.

The quad helix expansion appliance used was a prefabricated, removable Wilson 3D quad helix made from 0.038" blue Elgiloy (Rocky Mountain Orthodontics, Denver, CO, USA) that is inserted into the vertical slots on the maxillary first molar bands, as described by Wilson and Wilson.¹⁵ The quad helix was expanded approximately 2–3 mm per month at each activation appointment. Generally, around 6 mm of expansion was initially achieved, and activation was continued until approximately 2–3 mm of overexpansion was achieved, as suggested by Bell and LeCompte.¹⁶ Once 2–3 mm of overexpansion was achieved, the quad helix was left in the mouth in a passive state for a minimum of 3 months to allow for expansion stabilization.

The bonded rapid maxillary expander used was an acrylic splint-type expander with acrylic posterior

Table 1. Inclusion and Exclusion Criteria

| Inclusion Criteria | Exclusion Criteria |
|--|---|
| Girls aged 7–12 y and boys aged 7–13 y ^a | Patients outside of the age range of 7–12 y for girls and 7–13 y for boys |
| Class I or Class II skeletal pattern | Any skeletal pattern other than class I or class II |
| Convexity (A-NPo) > 0 mm | Convexity (A-NPo) < 0 mm |
| Facial axis (NaBa-PtGn) ≤ 88° | Facial axis (NaBa-PtGn) > 88° |
| Ricketts total facial height (NaBa-XiPm) ≥ 60° | Ricketts total facial height (NaBa-XiPm) < 60° |
| Treated with palatal expansion as phase I treatment | Missing pretreatment or posttreatment cephalometric films |
| Lateral cephalometric radiographs taken before treatment and after completion of expansion | Craniofacial anomalies that may impact cephalometric tracings |
| Phase I orthodontic treatment only, prior to any phase II orthodontic treatment | Any patients treated with SARPE |

^a y indicates years.

coverage and an expansion screw located in the center of the palate. The bonded rapid maxillary expander was activated with two turns per day (0.25 mm per turn, 0.5 mm per day) until the desired amount of expansion was achieved, typically around 6 mm. Generally, patients in this treatment group were not overexpanded. Once the desired expansion was achieved, the bonded expander was stabilized in a passive state for a minimum of 5 months to allow for expansion stabilization.

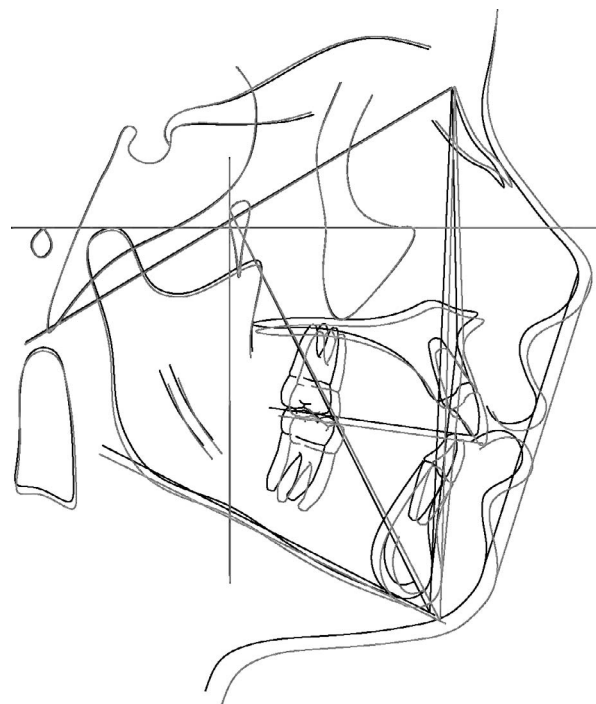
Intrareliability of the primary investigator with regard to cephalometric tracing was tested by tracing and comparing 10 different lateral cephalograms at two different time points, approximately 2 weeks apart. Interreliability was also tested between the primary investigator and an orthodontic faculty member at the University of Illinois at Chicago. The primary investigator and the faculty member each traced the same 10 lateral cephalograms, and the two tracings were compared.

The vertical dimension changes in this study were assessed using the following eight cephalometric measurements: convexity (Point A to Nasion to Pogonion Plane [A-NPo]), U6 to Palatal Plane (PP), Lower First Molar to Mandibular Plane (L6-MP), Ricketts total facial height (NaBa-XiPm), lower facial height (Angle between Anterior Nasal Spine and Xi-Pm [ANS-Xi-PM]), facial axis (Angle between Nasion to Basion and Pt to Gnathion [NaBa-PtGn]), Angle between Nasion to Point A and Nasion to Point B (ANB), and Frankfort-mandibular plane angle (MP-FH).

To minimize landmark identification error and to ensure that each cephalometric tracing was as accurate as possible, the transfer structures function in Dolphin Imaging was used.¹⁷ After each cephalogram was calibrated (for magnification), traced, and oriented parallel to the Frankfort-horizontal plane, all supposedly stable structures were transferred throughout all of the cephalometric radiographs for both the quad helix and the bonded expander groups at T1 and T2 for accurate analysis.

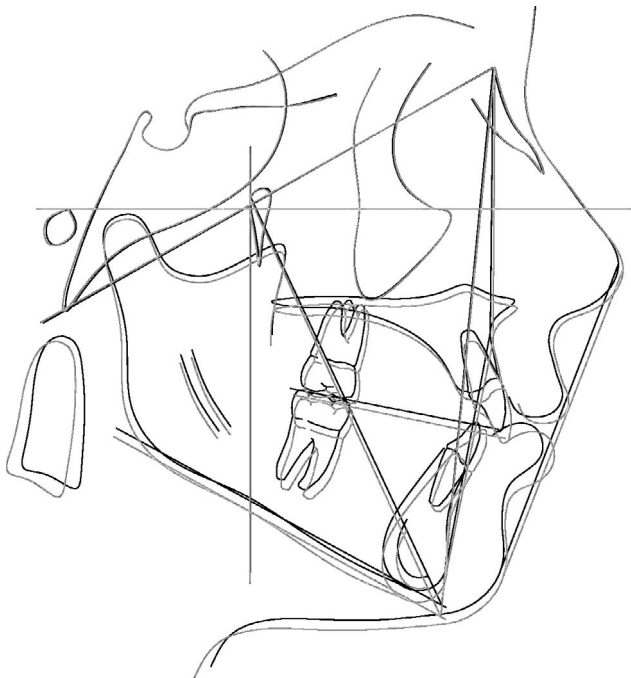
Average composite tracings were created for the quad helix group and bonded expander group prior to creating the untreated growth predictions. All of the T1 lateral cephalogram tracings for each group were superimposed on each other in Dolphin Imaging, and the average function was selected to create an average composite cephalometric tracing for each group at T1 and T2 for the quad helix group (Figures 1 and 2) and for the bonded expander group (Figures 3 and 4).

To determine the untreated predicted growth of the quad helix group and the bonded expander group, the



Average Quad Helix T1
Average Quad Helix T2

Figure 1. Average cephalometric tracings for quad helix group before treatment (T1) and at the completion of phase I treatment (T2).



Average Bonded Expander T1
Average Bonded Expander T2

Figure 2. Average cephalometric tracings for bonded expander group before treatment (T1) and at the completion of phase I treatment (T2).

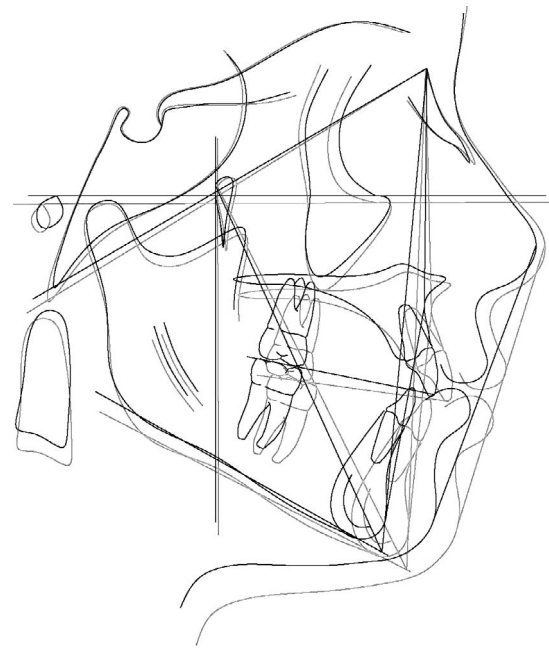
Ricketts growth prediction module in Dolphin Imaging was used. This Ricketts growth prediction module has been studied and shown to be effective in predicting growth within 2 years, which is the treatment time range into which our sample falls.¹⁷⁻²²

All cephalometric radiographs were traced and analyzed at two different time points, T1 and T2. Data were analyzed to determine if any significant differences existed between the quad helix expander and the bonded rapid maxillary expander groups, especially regarding vertical changes during treatment. IBM SPSS Statistics for Windows Version 22.0 (IBM Corp., Armonk, NY) was used for the statistical analysis.

RESULTS

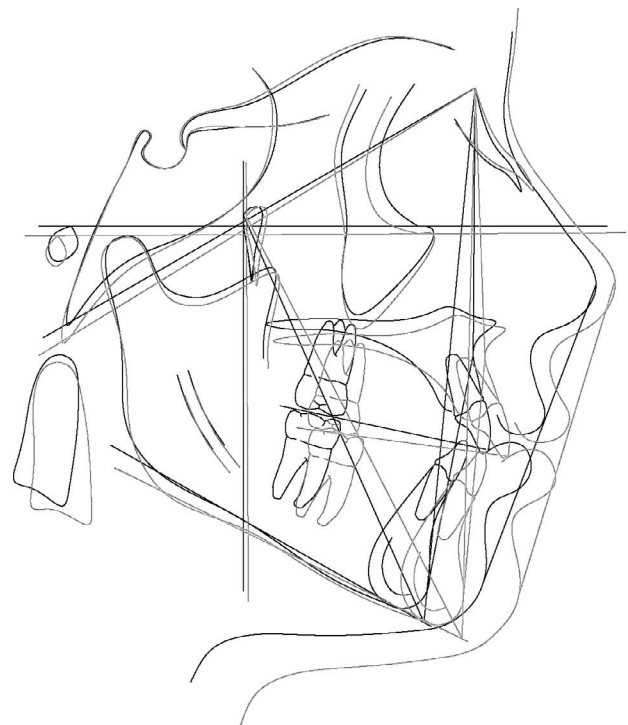
Descriptive statistics were computed for all of the variables used in the study, and a Shapiro-Wilk test supported the hypothesis of normality for the study variables. Intra- and interclass correlation coefficients were higher than .85, with the 95% confidence interval ranging from .445 to .998 among the study variables. A *P* value of less than or equal to .05 was set for statistical significance in the study analyses.

The mean age at T1 and mean treatment time were calculated for each group, and independent *t*-tests were performed to evaluate whether there was a



Average Quad Helix T1
Average Bonded Expander T1

Figure 3. Average cephalometric tracings for quad helix group and bonded expander group before treatment (T1).



Average Bonded Expander T2
Average Quad Helix T2

Figure 4. Average cephalometric tracings for quad helix group and bonded expander group at the completion of phase I treatment (T2).

Table 2. Independent *t*-Tests for Age Before Treatment (T1), at the Completion of Phase I Treatment (T2), and Treatment Time Between Quad Helix and Bonded Expander (Months)

| Variables | Quad Helix | | Bonded Expander | | Mean Difference | <i>P</i> Value |
|----------------|------------|-----------------|-----------------|-------|-----------------|----------------|
| | Mean | SD ^a | Mean | SD | | |
| Age at T1 | 114.82 | 20.96 | 102.89 | 8.90 | 11.94 | .041* |
| Age at T2 | 134.02 | 22.48 | 118.13 | 10.66 | 15.89 | .015* |
| Treatment time | 20.00 | 9.13 | 12.28 | 8.29 | 7.72 | .013* |

^a SD indicates standard deviation.
* Statistically significant at *P* value < .05.

statistically significant mean difference between the mean ages and mean treatment times of the two groups at T1. The results are shown in Table 2. Age at T1 showed a mean difference of 11.94 months (*P* = .041), and treatment time showed a mean difference of 7.72 months (*P* = .013). Age at T2 showed a mean difference of 7.72 months (*P* = .015).

A paired-samples *t*-test was performed to evaluate whether there was a statistically significant mean difference between time points T1 and T2 within each treatment group. Table 3 summarizes the means, standard deviations, mean differences, and *P* values from T1 to T2 within each treatment group. For the quad helix expander group, no statistically significant differences were found for any variables from T1 to T2. For the bonded rapid maxillary expander group, a statistically significant difference was found for the variable L6-MP, which showed a mean difference of 0.87 mm (*P* = .004), with a higher mean at T2.

Independent *t*-tests were performed to evaluate whether there was a statistically significant mean difference between the quad helix expander group

and the bonded rapid maxillary expander group at both T1 and T2. Table 4 summarizes the findings at T1 and at T2.

No variables were found to have statistically significant mean differences at T1 between the two groups. Five variables were found to have statistically significant mean differences at T2 between the two groups. Convexity showed a mean difference of -1.46 mm (*P* = .040), total facial height showed a mean difference of -2.28° (*P* = .017), lower facial height showed a mean difference of -2.28° (*P* = .027), facial axis showed a mean difference of 1.85° (*P* = .037), and FMA showed a mean difference of -3.03° (*P* = .015).

One-sample *t*-tests were performed to evaluate whether there was a statistically significant mean difference between the Ricketts growth prediction for T2 based on the initial T1 values and the actual results that were found at T2 for each group. Table 5 summarizes the results for the quad helix and bonded expander groups.

For the quad helix group, a statistically significant mean difference was found for the lower facial height variable, which showed a mean difference of -2.12° (*P* = .017), with a higher mean for the Ricketts untreated predicted growth for T2. For the bonded rapid maxillary expander group, a statistically significant mean difference was found for the variable U6-PP, which showed a mean difference of -1.21 mm (*P* = .024), with a higher mean for the Ricketts untreated predicted growth for T2.

DISCUSSION

A statistically significant mean difference was found for mean age at T1, and this difference may be clinically

Table 3. Paired-Samples *t*-Tests for Quad Helix and Bonded Expander Between T1 and T2^a

| Cephalometric Measurements | Quad T1 | | Quad T2 | | Quad T2-T1 | | Bonded T1 | | Bonded T2 | | Bonded T2-T1 | |
|--|---------|-----------------|---------|------|-----------------|----------------|-----------|------|-----------|------|-----------------|----------------|
| | Mean | SD ^a | Mean | SD | Mean Difference | <i>P</i> Value | Mean | SD | Mean | SD | Mean Difference | <i>P</i> Value |
| | | | | | | | | | | | | |
| Convexity (A-NPo) mm | 3.44 | 2.01 | 3.47 | 1.90 | 0.04 | .887 | 4.48 | 2.25 | 4.93 | 2.12 | 0.44 | .072 |
| U6-PP mm | 19.94 | 3.07 | 20.26 | 2.77 | 0.33 | .379 | 19.62 | 1.79 | 19.29 | 2.07 | -0.33 | .338 |
| L6-MP mm | 27.45 | 2.53 | 28.15 | 2.85 | 0.70 | .095 | 26.79 | 2.61 | 27.66 | 2.62 | 0.87 | .004* |
| Total facial height (NaBa-XiPm), degrees | 64.41 | 2.83 | 63.56 | 2.88 | -0.85 | .227 | 65.92 | 2.27 | 65.84 | 2.49 | -0.07 | .861 |
| Lower facial height (ANS-Xi-Pm), degrees | 47.39 | 3.10 | 46.16 | 3.27 | -1.24 | .109 | 48.28 | 3.13 | 48.67 | 3.16 | 0.38 | .322 |
| Facial axis (NaBa-PtGn), degrees | 84.88 | 2.14 | 85.49 | 2.66 | 0.61 | .234 | 84.07 | 2.22 | 83.64 | 2.38 | -0.43 | .063 |
| ANB, degrees | 4.15 | 1.67 | 4.14 | 1.49 | -0.01 | .967 | 4.96 | 2.11 | 5.11 | 1.93 | 0.15 | .587 |
| FMA (MP-FH), degrees | 27.45 | 4.15 | 26.52 | 4.21 | -0.92 | .138 | 29.26 | 2.32 | 29.55 | 2.60 | 0.29 | .311 |

^a T1 indicates before treatment; T2, completion of phase I treatment; SD, standard deviation; MP-FH, Frankfort-mandibular plane angle; A-NPo, Point A to Nasion to Pogonion Plane; PP, Palatal Plane; L6-MP, Lower First Molar to Mandibular Plane; ANS-Xi-PM, Angle between Anterior Nasal Spine and Xi-Pm; NaBa-PtGn, Angle between Nasion to Basion and Pt to Gnation; ANB, Angle between Nasion to Point A and Nasion to Point B.

* Statistically significant at *P* value ≤ .05.

Table 4. Independent *t*-Tests Between Quad Helix and Bonded Expander Groups at T1 and T2^a

| Cephalometric Measurements | Quad Helix T1 (n = 17) | | Bonded Expander T1 (n = 18) | | Group Difference T1 | | Quad Helix T2 (n = 17) | | Bonded Expander T2 (n = 18) | | Group Difference T2 | |
|--|------------------------|-----------------|-----------------------------|------|---------------------|----------------|------------------------|------|-----------------------------|------|---------------------|-------------------|
| | Mean | SD ^a | Mean | SD | Mean Difference | <i>P</i> Value | Mean | SD | Mean | SD | Mean Difference | <i>P</i> Value |
| | | | | | | | | | | | | |
| Convexity (A-NPo) mm | 3.44 | 2.01 | 4.48 | 2.25 | -1.05 | .157 | 3.47 | 1.90 | 4.93 | 2.12 | -1.46 | .040* |
| U6-PP mm | 19.94 | 3.07 | 19.62 | 1.79 | 0.31 | .713 | 20.26 | 2.77 | 19.29 | 2.07 | 0.98 | .245 |
| L6-MP mm | 27.45 | 2.53 | 26.79 | 2.61 | 0.66 | .451 | 28.15 | 2.85 | 27.66 | 2.62 | 0.49 | .599 |
| Total facial height (NaBa-XiPm), degrees | 64.41 | 2.83 | 65.92 | 2.27 | -1.50 | .091 | 63.56 | 2.88 | 65.84 | 2.49 | -2.28 | .017 [†] |
| Lower facial height (ANS-Xi-Pm), degrees | 47.39 | 3.10 | 48.28 | 3.13 | -0.89 | .405 | 46.16 | 3.27 | 48.67 | 3.16 | -2.51 | .027 [†] |
| Facial axis (NaBa-PtGn), degrees | 84.88 | 2.14 | 84.07 | 2.22 | 0.80 | .284 | 85.49 | 2.66 | 83.64 | 2.38 | 1.85 | .037 [†] |
| ANB, degrees | 4.15 | 1.67 | 4.96 | 2.11 | -0.81 | .216 | 4.14 | 1.49 | 5.11 | 1.93 | -0.98 | .104 |
| FMA (MP-FH), degrees | 27.45 | 4.15 | 29.26 | 2.32 | -1.81 | .119 | 26.52 | 4.21 | 29.55 | 2.60 | -3.03 | .015 [†] |

^a T1 indicates before treatment; T2, completion of phase I treatment; SD, standard deviation; MP-FH, Frankfort-mandibular plane angle; A-NPo, Point A to Nasion to Pogonion Plane; PP, Palatal Plane; L6-MP, Lower First Molar to Mandibular Plane; ANS-Xi-PM, Angle between Anterior Nasal Spine and Xi-Pm; NaBa-PtGn, Angle between Nasion to Basion and Pt to Gnasion; ANB, Angle between Nasion to Point A and Nasion to Point B.

* Statistically significant at *P* value ≤ .05.

important because it is generally easier and more beneficial to perform palatal expansion at a younger age, prior to puberty.²³ Treatment time was found to be significantly longer for the quad helix group; therefore, the influence of growth may have been greater.

No statistically significant mean differences were found at the T1 to T2 comparison of the quad helix group. One variable (L6-MP) was found to have a statistically significant mean difference at the T1 to T2 comparison of the bonded expander group, indicating some extrusion of L6 after expansion was complete.

The results of the independent *t*-test that compared the quad helix expander group and the bonded rapid maxillary expander group at T1 showed that there were no significant mean differences between the two

groups, indicating that both groups were similar enough to compare with each other.

The independent *t*-test that compared the quad helix expander group and the bonded rapid maxillary expander group at T2 showed significant mean differences for the following five variables: convexity, lower facial height, total facial height, facial axis, and FMA. Convexity was significantly greater for the bonded expander group at T2 than for the quad helix group, showing a greater difference in the relationship between the maxilla and mandible and therefore a greater tendency toward a class II skeletal pattern. Lower facial height was significantly greater for the bonded expander group at T2 than for the quad helix group.

Table 5. One-Sample *t*-Tests Between Ricketts Untreated Predicted Growth Value and Sample Means at T2^a for Quad Helix and Bonded Expander

| Cephalometric Measurements | Quad Untreated Predicted Growth | Quad Helix T2 | Group Difference | | Bonded Untreated Predicted Growth | Bonded Expander T2 | Group Difference | |
|--|---------------------------------|---------------|------------------|-------------------|-----------------------------------|--------------------|------------------|----------------|
| | Mean | Mean | Mean Difference | <i>P</i> Value | Mean | Mean | Mean Difference | <i>P</i> Value |
| | | | | | | | | |
| Convexity (A-NPo) mm | 3.42 | 3.47 | 0.05 | .914 | 4.47 | 4.93 | 0.46 | .372 |
| U6-PP mm | 21.55 | 20.26 | -1.29 | .074 | 20.50 | 19.29 | -1.21 | .024* |
| L6-MP mm | 28.83 | 28.15 | -0.68 | .342 | 27.52 | 27.66 | 0.14 | .822 |
| Total facial height (NaBa-XiPm), degrees | 64.42 | 63.56 | -0.86 | .238 | 65.92 | 65.84 | -0.08 | .899 |
| Lower facial height (ANS-Xi-Pm), degrees | 48.28 | 46.16 | -2.12 | .017 [†] | 48.80 | 48.67 | -0.13 | .860 |
| Facial axis (NaBa-PtGn), degrees | 84.89 | 85.49 | 0.60 | .368 | 84.17 | 83.64 | -0.53 | .356 |
| ANB, degrees | 3.98 | 4.14 | 0.16 | .672 | 4.8 | 5.11 | 0.31 | .503 |
| FMA (MP-FH), degrees | 28.18 | 26.52 | -1.66 | .125 | 29.75 | 29.55 | -0.20 | .748 |

^a T2 indicates completion of phase I treatment; MP-FH, Frankfort-mandibular plane angle; A-NPo, Point A to Nasion to Pogonion Plane; PP, Palatal Plane; L6-MP, Lower First Molar to Mandibular Plane; ANS-Xi-PM, Angle between Anterior Nasal Spine and Xi-Pm; NaBa-PtGn, Angle between Nasion to Basion and Pt to Gnasion; ANB, Angle between Nasion to Point A and Nasion to Point B.

* Statistically significant at *P* value ≤ .05.

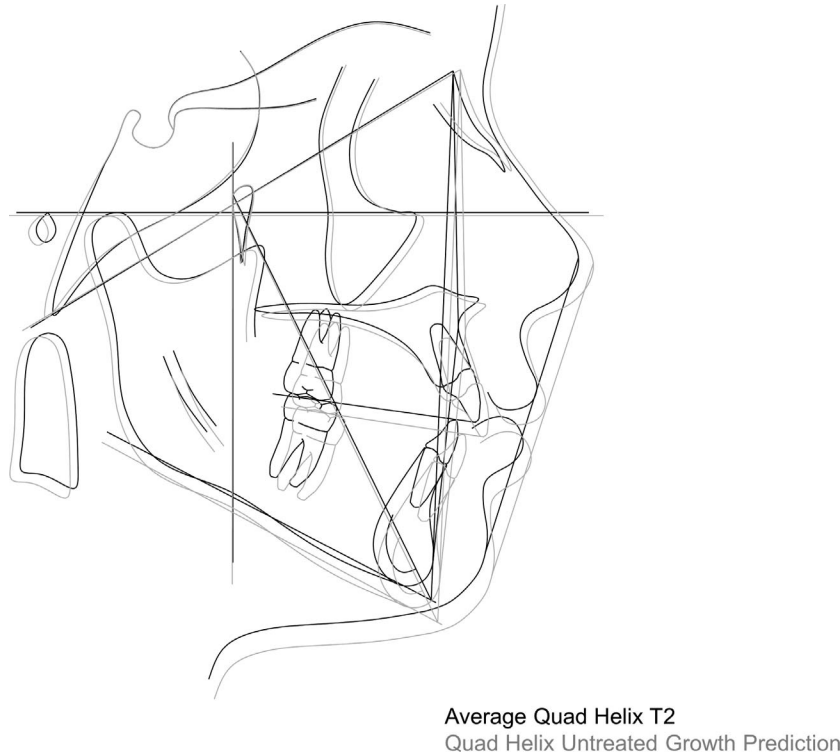


Figure 5. Quad helix cephalometric tracing for treated and growth-predicted untreated average.

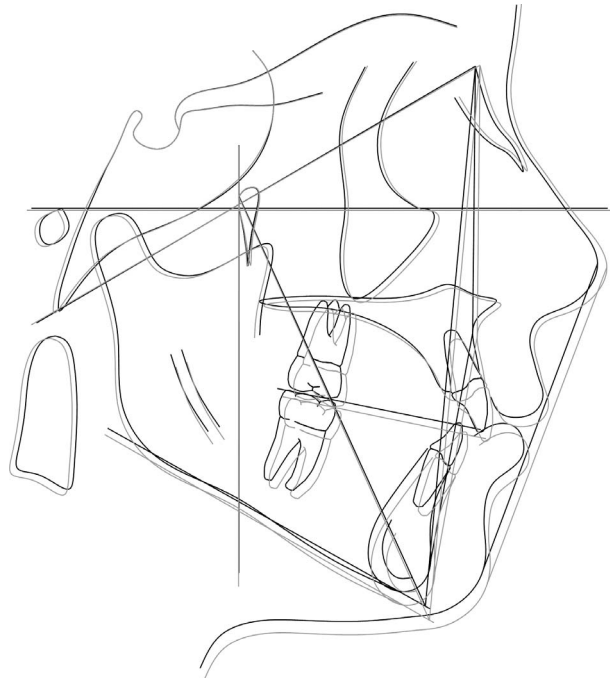
Total facial height was significantly greater for the bonded expander group at T2 than for the quad helix group. Because the bonded expander was slightly above the normal range, it indicated a slightly increased total facial height and therefore a slightly increased mandibular body position with respect to the cranial base. The facial axis value was significantly greater for the quad helix group at T2, indicating that the growth tendency for the mandible and chin was less vertical for the quad helix group than for the bonded expander group. The FMA value was significantly greater for the bonded expander group at T2, but both groups were within the normal range. However, the bonded expander group value was at the upper limit of the range, indicating a tendency toward a more vertical growth pattern.

To compare the effects of quad helix treatment to untreated predicted growth, the Ricketts growth prediction analysis was used to simulate untreated patients based on the mean T1 values of each treatment group. Studies have been done validating the utilization of the Ricketts computerized growth prediction analysis for 2 years or less prediction, which is comparable with longitudinal control untreated group data such as the one available in the American Association of Orthodontists Foundation Legacy collection.¹⁷⁻²¹ The only statistically significant variable

found between the untreated predicted growth and the actual treatment value at T2 was lower facial height, which was significantly lower for the quad helix actual treatment value (Figure 5).

Because lower facial height is a measurement indicating skeletal open bite or deep bite, it is advantageous to maintain lower facial height within the normal range during treatment so an ideal skeletal bite is achieved. The quad helix treatment appears to have maintained a more ideal lower facial height than untreated growth alone; therefore, treatment with a quad helix expander appears to maintain or even improve lower facial height. The only statistically significant variable found between the untreated predicted growth and the actual treatment value at T2 for the bonded expander group was U6-PP, which statistically was significantly lower for the bonded expander actual treatment value (Figure 6).

Because the bonded expander treatment group had a statistically significant lower value for U6-PP than the untreated predicted growth value, it indicates that treatment with a bonded expander can result in significant intrusion of the maxillary first molar. Wending et al.¹⁴ showed a similar significant intrusion of the maxillary first molar using a bonded rapid maxillary expander. In patients with an existing increased vertical dimension, whether it is skeletal or dental in



Bonded Expander Untreated Growth Prediction
Average Bonded Expander T2

Figure 6. Bonded expander cephalometric tracing for treated and growth-predicted untreated average.

origin, intrusion of the maxillary first molar would be beneficial during orthodontic treatment so that the vertical dimension can be maintained or improved.

CONCLUSIONS

- Overall, both the quad helix expander and the bonded rapid maxillary expander showed minimal vertical changes during palatal expansion treatment.
- When comparing treatment results after phase I orthodontic treatment, five variables showed statistically significant mean differences between the quad helix and the bonded expander groups: convexity, lower facial height, total facial height, facial axis, and FMA. Based on this sample, the differences in these variables suggested that the quad helix expander had more control over skeletal vertical measurements than the bonded rapid maxillary expander.
- When comparing treatment results to untreated predicted growth values, the quad helix expander appeared to maintain lower facial height better than the bonded rapid maxillary expander, and the bonded rapid maxillary expander appeared to maintain the maxillary first molar vertical height better than the quad helix expander.
- Therefore, it can be said that both the quad helix expander treatment and the bonded rapid maxillary expander treatment during phase I orthodontic

treatment adequately maintained the vertical dimension in growing skeletal class I and class II patients.

REFERENCES

1. Haas AJ. Rapid expansion of the maxillary dental arch and nasal cavity by opening the midpalatal suture. *Angle Orthod.* 1961;31:73–90.
2. Ladner PT, Muhl ZF. Changes concurrent with orthodontic treatment when maxillary expansion is a primary goal. *Am J Orthod Dentofacial Orthop.* 1995;108:184–193.
3. Haas AJ. The treatment of maxillary deficiency by opening the midpalatal suture. *Angle Orthod.* 1965;35:200–217.
4. Wertz RA. Skeletal and dental changes accompanying rapid midpalatal suture opening. *Am Orthod.* 1970;58:41–66.
5. Haas AJ. Palatal expansion: just the beginning of dentofacial orthopedics. *Am J Orthod.* 1970;57:219–255.
6. Sandikçiolu M, Hazar S. Skeletal and dental changes after maxillary expansion in the mixed dentition. *Am J Orthod Dentofacial Orthop.* 1997;111:321–327.
7. Majourau A, Nanda R. Biomechanical basis of vertical dimension control during rapid palatal expansion therapy. *Am J Orthod Dentofacial Orthop.* 1994;106:322–328.
8. Angell E. Treatment of irregularity of the permanent or adult teeth. *Dent Cosmos.* 1860;1:540–544.
9. Brandt S, Ricketts RM. Interview: Dr. Robert M. Ricketts on growth prediction 2. *J Clin Orthod.* 1975;9:340–349, 352–362.
10. Bench RW. The quad helix appliance. *Sem Orthod.* 1998;4:231–237.
11. Hicks EP. Slow maxillary expansion: a clinical study of the skeletal versus dental response to low-magnitude force. *Am J Orthod.* 1978;73:121–141.

12. Storey E. Tissue response to the movement of bones. *Am J Orthod.* 1973;64:229–247.
13. Proffit W, Fields H, Sarver D. *Contemporary Orthodontics*. 4th ed. St Louis, Mo.: Mosby Elsevier; 2007:499–501.
14. Wendling LK, McNamara JA Jr, Franchi L, Baccetti T. A prospective study of the short-term treatment effects of the acrylic-splint rapid maxillary expander combined with the lower schwarz appliance. *Angle Orthod.* 2005;75:7–14.
15. Wilson WL, Wilson RC. Modular 3D lingual appliances. Part 1. Quad helix. *J Clin Orthod.* 1983;17:761–766.
16. Bell RA, LeCompte EJ. The effects of maxillary expansion using a quad-helix appliance during the deciduous and mixed dentitions. *Am J Orthod.* 1981;79:152–161.
17. Sagun M, Kusnoto B, Galang MT, Viana G, Evans CA. Comparison of computerized cephalometric growth prediction: a study of three methods. *J World Fed Orthod.* 2015;4:146–150.
18. Schulhof RJ, Bagha L. A statistical evaluation of the Ricketts and Johnston growth forecasting methods. *Am J Orthod.* 1975;67:258–276.
19. Greenberg LA, Johnston LE. Computerized prediction: the accuracy of a contemporary long-range forecast. *Am J Orthod.* 1975;67:243–252.
20. Kocadereli I, Telli AE. Evaluation of Ricketts long-range growth prediction in Turkish children. *Am J Orthod Dentofacial Orthop.* 1999;115:515–520.
21. Turchetta BJ, Fishman LS, Subtelny JD. Facial growth prediction: a comparison of methodologies. *Am J Orthod Dentofacial Orthop.* 2007;132:439–449.
22. Parikakis KA, Svante M, Hellsing E. Evaluation of the variable anchorage straightwire technique. *Eur J Orthod.* 2009;31:76–83.
23. Bell RA. A review of maxillary expansion in relation to rate of expansion and patient's age. *Am J Orthod.* 1982;81:32–37.